

## SKELETAL LESIONS AND DEFORMITIES IN LARGE SHARKS

John M. Hoenig<sup>1</sup> and Alexander H. Walsh<sup>2</sup>

**ABSTRACT:** Four blunt-snouted sandbar sharks (*Carcharhinus plumbeus*) were noted among 555 examined over a 13-yr period. Radiographs of one specimen revealed that the three rostral cartilage rods were abnormally short and failed to join at the anterior tip. The deformity appeared to be congenital. Four cases of vertebral lesions were noted in three species of shark (*Carcharhinus plumbeus*, *Negaprion brevirostris* and *Odontaspis taurus*). The vertebral columns had fused centra, ribs and neural arches, extra deposition and erosion of calcified material in the centra, and in one case, compression of centra. The causes of the vertebral lesions are unknown.

### INTRODUCTION

The causes of mortality in large sharks are poorly known because sharks generally have low commercial value and are often difficult to obtain for study (Springer, 1960; Ronsivalli, 1978). Occasionally, obviously deformed specimens and specimens with internal abnormalities discovered incidentally during dissection have been described (Dawson, 1964, 1966, 1971, 1976), but extensive work remains to be done. Skeletal pathology is of particular interest to the fisheries biologist since the hard parts frequently contain growth marks used for age determinations (Stevens, 1975; Hoenig, 1979).

While conducting studies on growth rings in shark vertebrae, the first author obtained one specimen with a deformed chondrocranium and four with vertebral lesions. Additional data on three cases of cranial deformity also were obtained. This paper describes the observed specimens and presents data on the frequency of occurrence of the cranial deformity.

### MATERIALS AND METHODS

The species, sex, length, weight, date and location of capture of the specimens are given in Table 1.

One specimen of a sandbar shark (*Carcharhinus plumbeus*, specimen #1) with a squared-off, blunt snout was obtained for examination at the 1977 Bayshore Mako Tournament, an annual fishing tournament held at Bayshore, Long Island, New York. A review of the fishing logs from the same tournament over the last 13 yr produced records of three more *C. plumbeus* with deformed snouts (specimens #2, 3, and 4).

The snout region of specimen #1 was examined for open wounds, scar tissue or other indications of

injury. The length and shape of the narial folds were noted and a radiograph was taken of the chondrocranium. The radiograph was compared to the dried chondrocranium from a normal *C. plumbeus*. Morphometric measurements were made according to the procedure in Bigelow and Schroeder (1948).

The four vertebral lesions were obtained from different sources. Unfortunately, each specimen was preserved differently (Table 1). Radiographs were taken of each specimen.

### RESULTS

Macroscopic examination of the head of the blunt-snouted *C. plumbeus* (specimen #1) revealed that the anterior edge of the snout was shortened and flattened and formed an abrupt angle at each side of the head (Fig. 1) instead of being round. Both nares were present although the right narial opening was smaller than the left. The radiograph (Fig. 2) showed that the cartilaginous rods that form the rostrum were abnormally short and failed to join together at the tip of the snout as in a normal rostrum. The pigmentation of the snout region was unremarkable and there were no external scars, open wounds, necrotic tissue, or other evidence of injury.

The morphometry of specimen #1 is given in Table 2. The measurements are similar to those given by Bigelow and Schroeder (1948) for two normal specimens except that the snout is about half as long as normal.

The most severe vertebral lesion was from *C. plumbeus* specimen #5. The external appearance of the shark was unremarkable. The bending and fusion of the ribs and the calcified swelling around the centra were noted at two locations during dissection of the shark (Fig. 3). A radiograph showing a dorsoventral view of the deformed sections is presented in Figure 4. The white "butterfly" in each centrum is the double cone of calcification or middle zone. The black triangles in the centrum are the peripheral calcifications (using Bidewood's (1921)

Received for publication 8 May 1981.

<sup>1</sup>Graduate School of Oceanography, University of Rhode Island, Kingston, Rhode Island 02881, USA.  
<sup>2</sup>Pfizer Central Research, Eastern Point Road, Groton, Connecticut 06340, USA, to whom reprint requests should be addressed.

TABLE 1. Capture data for specimens of sharks examined during this study.

Specimen #	Species	Date collected	Sex	Total length (cm)	Total weight (kg)	Location	Remarks
1	<i>Carcharhinus plumbeus</i>	6/29/77	F	173.0	30	Long Island, NY	blunt snout; head saved
2	<i>Carcharhinus plumbeus</i>	6/28/75	F	125.1	15	Long Island, NY	blunt snout; specimen discarded
3	<i>Carcharhinus plumbeus</i>	6/27/71	?	173.6	32	Long Island, NY	blunt snout; specimen discarded
4	<i>Carcharhinus plumbeus</i>	6/28/70	?	139.7	25	Long Island, NY	blunt snout; specimen discarded
5	<i>Carcharhinus plumbeus</i>	8/12/78	F	195.0	NR*	Long Island, NY	vertebral lesion, column preserved in formalin
6	<i>Carcharhinus plumbeus</i>	7/29/63	F	about 215 cm	NR	East Coast, US	vertebral lesion, column dried
7	<i>Negaprion brevirostris</i>	7/12/77	F	267.7	NR	Mobile, Alabama	vertebral lesion, column preserved in alcohol
8	<i>Odontaspis taurus</i>	8/26/77	M	207.0	37	Delaware Bay	vertebral lesion, column x-rayed and discarded

\* NR = not recorded.

TABLE 2. Comparison of proportional dimensions of a blunt-snouted sandbar shark (*C. plumbeus*, specimen #1) with two normal specimens.

Sex, total length	Specimen #1 F, 1,730 mm	Normal specimen* M, 743 mm	Normal specimen* M, 1,496 mm
Distance from snout <sup>b</sup> to	mm	% TL	% TL
Eyes	72	4.2	—
Nostrils	28	1.6	4.1
Mouth	79	4.6	8.2
Pectoral	351	20.2	24.7
1st dorsal	477	27.5	28.3
2nd dorsal	1,082	62.5	60.5
Pelvic	845	48.8	49.1
Anal	1,068	61.7	61.5
Upper caud. pit	1,252	72.4	73.3
1st gill (bottom)	276	16.0	—
Interspace between:			
1st and 2nd dorsal	599	23.1	20.7
2nd dorsal and caudal	190	7.5	7.4
Pelvic and anal	131	7.6	—
Anal and caudal	114	6.6	7.4
Nostrils	91	5.3	5.9
Height of:			
First dorsal	244	12.9	10.9
Second dorsal	59	3.4	3.1
Horizontal diam. eye	31	1.8	2.1
Gill openings length:			
First	—	—	3.0
Second	57	3.3	—
Third	52	3.0	—
Fourth	56	3.2	—
Fifth	52	3.0	2.5
Girth	706	40.5	—
Tooth formula	14-14/14-14		

\* Proportional dimensions of the normal specimens are taken from Bigelow and Schroeder (1948).

<sup>b</sup> All measurements from the snout are taken from the center of the snout. The left side of the snout protrudes 4 mm farther out than the center and the right side protrudes 3 mm less than the center. Thus the snout-nostril distance is 32 mm on the left, 28 mm in the center and 25 mm on the right.

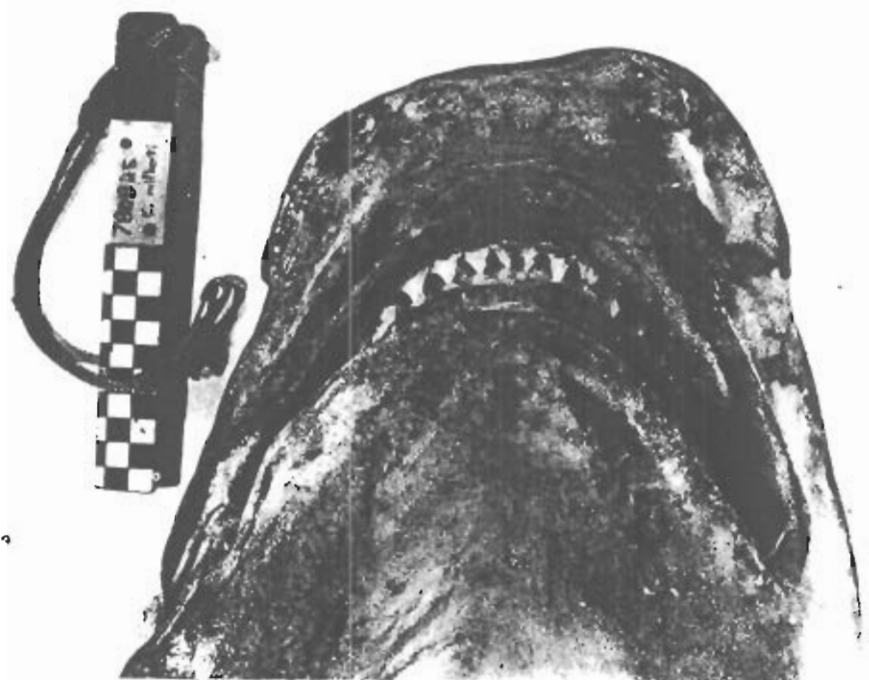

FIGURE 1. Photograph of head of deformed sandbar shark (*C. plumbeus*, specimen #1) showing shortened, angular snout.

nomenclature). The section in the top of the figure, from the region around the gill slits, shows severe fusion and compression of at least a dozen centra. The lower section of the figure, from the region at the caudal end of the visceral cavity, shows fusion and compression of the centra where the column undergoes slight lateral bending (scoliosis). Anterior to the region of bending (to the left in the figure) only two centra are fused. However, the centra show erosion and extra deposition of calcified material.

Only one vertebral lesion was noted in the other specimen of *C. plumbeus* (specimen #6) but the complete vertebral column was not available for study. The lesion appears as a swollen, fused mass. The radiograph (Fig. 5, lateral view) shows no evidence of fusion or compression of the centra. The configuration of the double cone of calcification is normal and there is no evidence of erosion of calcified material. The lesion appears to consist of deposition of extra calcified material in the peripherally calcified zone of the centrum (outside the notochordal sheath) and in the arch bases. The slight misalignment and irregular spacing

between the centra is probably an artifact of drying.

The *N. brevirostris* shark (specimen #7) appeared normal when collected. The section of the vertebral column was obtained for an age determination study. Removal of muscle tissue from the column revealed that the ribs were bent into a wavy pattern instead of being in a straight horizontal row. Radiography revealed a minor degree of erosion and extra deposition of calcified material in the peripheral calcified region of some of the centra and possibly some calcification of the cartilage associated with the ribs (transverse processes).

The *O. taurus* shark (specimen #8) appeared normal at capture. Two regions of swelling were discovered along the vertebral column during dissection but the entire column was not examined. Radiographs were taken of the two deformed regions (Fig. 6). Unfortunately, both the carcass and the vertebral sections were accidentally discarded before further analysis could be made. The radiograph shows three centra with extra deposition of calcified material. The double cones of calcification (middle zones) are

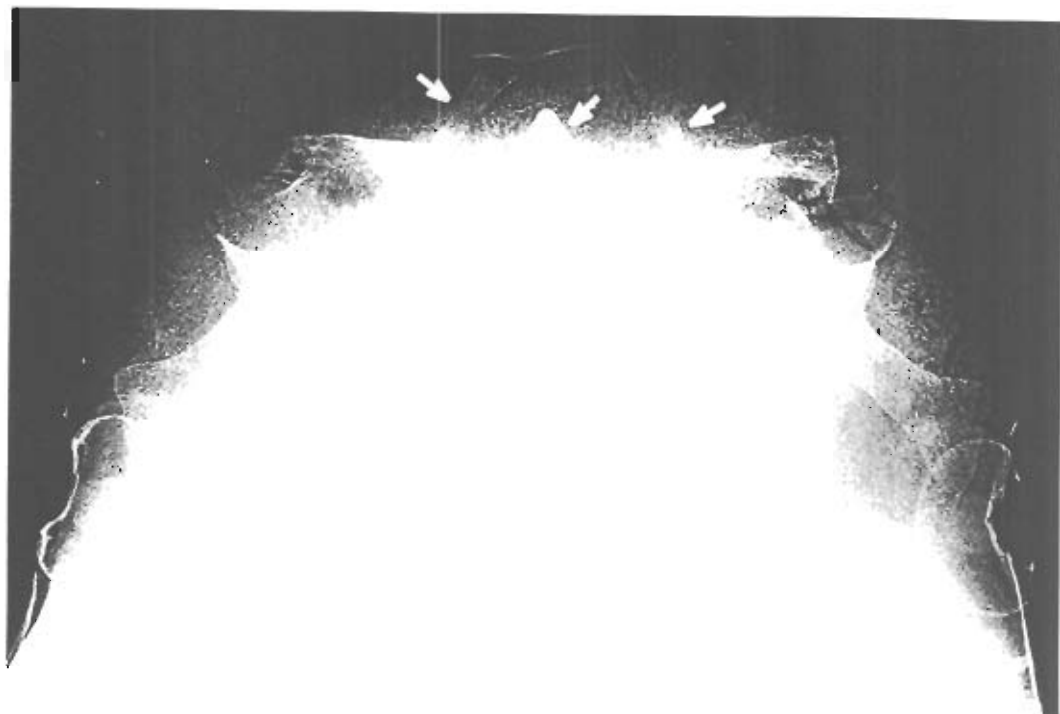


FIGURE 2. Radiograph of head of deformed sandbar shark (*C. plumbeus*, specimen #1) showing shortened rostral rods (arrows) that fail to communicate at the anterior tip.

still evident in the affected centra and there is no evidence of fusion. The parallel white streaks running antero-posteriorly in the normal centra are the calcified lamellae in the peripheral zone (i.e., outside the notochordal sheath) that are characteristic of the vertebrae of the oreo-lobid derived sharks (Applegate, 1967).

#### DISCUSSION

The snout deformity appears to be a congenital condition that affects only the snout region since there was no evidence of disease, injury or other abnormality. The other three records of blunt-snouted *C. plumbeus* are presumed to represent the same congenital condition since photographs show these specimens to be similar in appearance to specimen #1. If so, then a rough estimate of the frequency of occurrence of this condition is four out of 555 (0.7%) *C. plumbeus* examined (from 1965 to 1977 at the Bayside Mako Tournament). This is a minimum estimate since no special effort was made to look for this condition and less pronounced cases may have been overlooked.

Blunt-snouted *C. plumbeus* have been reported by Lawler (1976) and Schwartz (1973). Lawler noted that both nares were present in both of his specimens though the shape of one naris and the configuration of the Ampullae of Lorenzini were abnormal due to the abnormal shape of the snout. He did not speculate on the origin of the deformity.

None of Lawler's (1976) or Schwartz's (1973) specimens were larger than 95 cm total length. This size corresponds to fish of age 5 yr or less if they are growing at the rate of normal fish (Lawler, 1976). Specimens #1 and 3 in this study were 173.0 and 175.0 cm total length, respectively, corresponding to an age of about 16 yr according to Lawler's (1976) growth curve. Thus, it would appear that this deformity, at the severity noted, does not greatly impair the ability of the shark to survive.

All four of the deformed-snout *C. plumbeus* in this study, and both of Lawler's (1976) specimens, were females. Schwartz's (1973) specimen was a male. The fact that more females than males were found with the deformity can

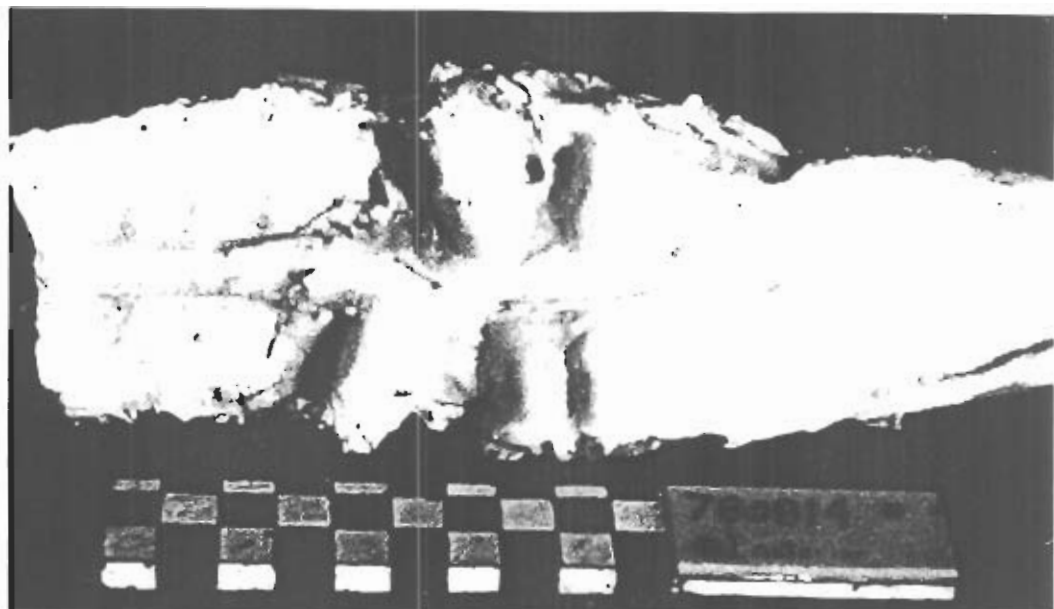


FIGURE 3. Photograph of a section of the vertebral column of *C. plumbeus*, specimen #5. The protruding bumps on the ventral surface are deformed ribs. Scale is in cm.

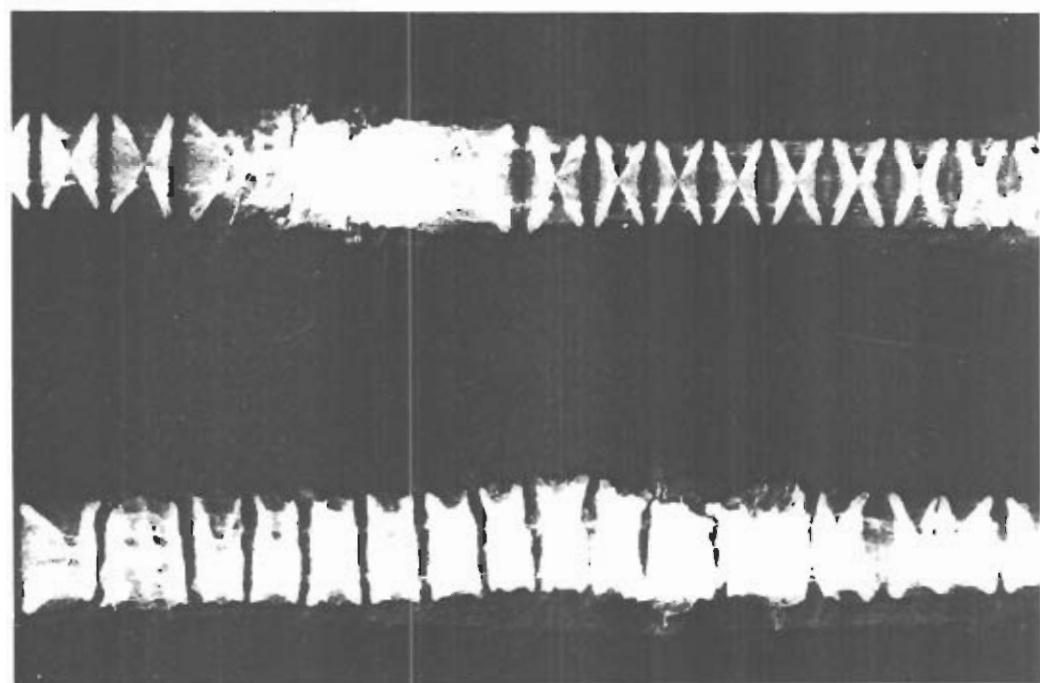


FIGURE 4. Radiograph showing dorso-ventral views of two sections of the vertebral column of *C. plumbeus*, specimen #5.

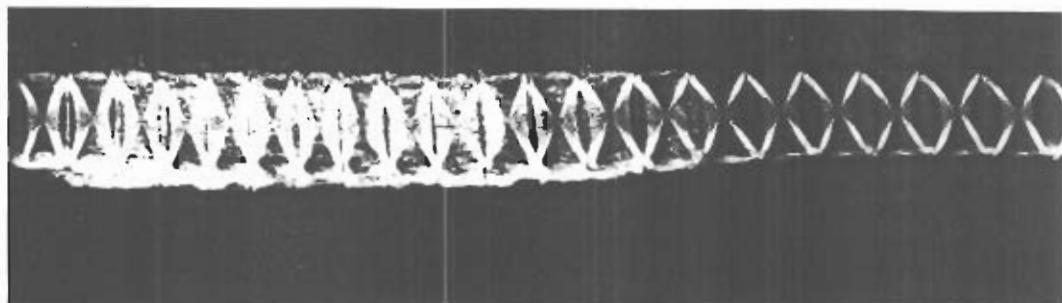


FIGURE 5 Radiograph showing lateral view of *C. plumbeus*, specimen #6

probably be attributed to the greater abundance of females in inshore waters (Springer, 1960).

The vertebral lesions noted in this study varied in severity. The mildest cases consisted of peripheral deposition of calcified material without modification of the basic structure of the centra (e.g., Fig. 5). The most severe case (Fig. 4) showed all of the following: erosion and deposition of calcified material, fusion of centra, compression (including formation of hemi-vertebrae) and scoliosis.

The etiology (or etiologies) of the vertebral lesions is not known. Vertebral lesions in sharks have occasionally been reported (Clark, 1964; Sadowsky, 1971; Schwartz, 1973). Schwartz (1973) speculated that diseases such as tuberculosis or salmonellosis, malnutrition, or injury may be the cause of the deformity he noted. There are many other possible causes. For example, myxosporidian parasites commonly invade the cartilage of teleost fish and could produce lesions of the spine resembling those noted in this study (Needham and Wootton,

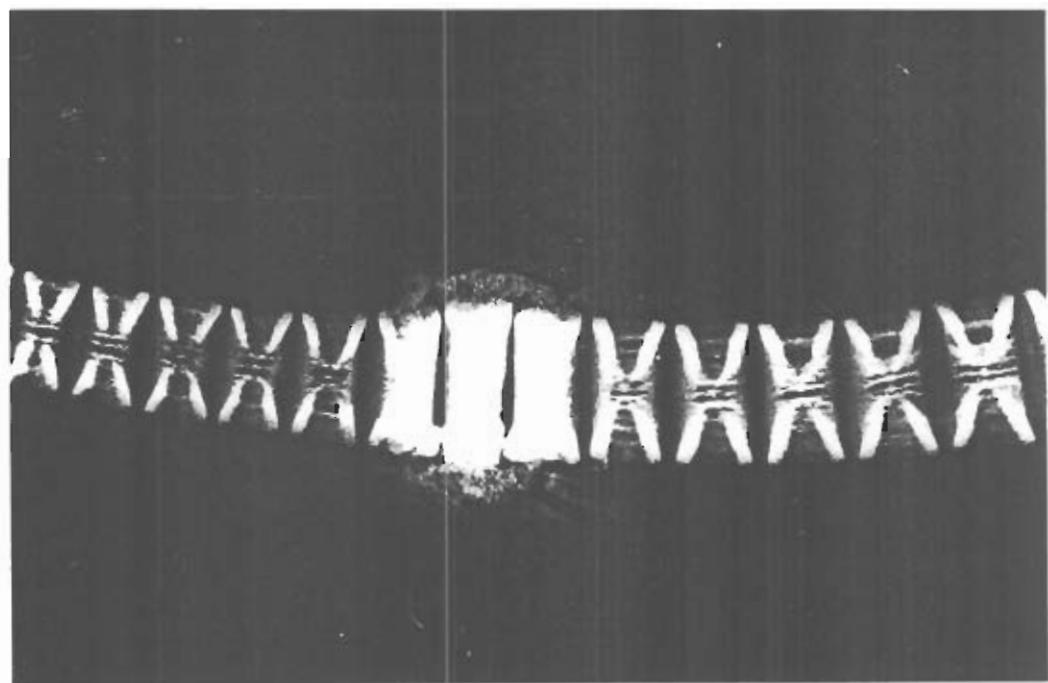


FIGURE 6 Radiograph of a section of the vertebral column of *O. taurus*, specimen #8. The mild bend in the column is an artifact of preservation.

1978). Alternatively, the lesions could represent arthritic changes associated with the aging process. In this regard, it is interesting to note that all four sharks in this study and those in Schwartz's (1973) and Clark's (1964) studies were fully mature adults and thus probably 20 yr old or more (Lawler, 1976; Hoenig, 1979). However, age related arthritic changes are more likely to be generalized rather than focal as seen in these four cases.

An estimate of the frequency of occurrence of vertebral lesions is not possible since no systematic effort was made to obtain specimens. The fact that we happened to come across four specimens suggests that these conditions must be common.

#### ACKNOWLEDGMENTS

The authors would like to thank Dr. Robert Stiles and Mr. John Casey for supplying specimens. Drs. William Krueger and Richard Wolke and Mr. Walter Laskey made radiographs and Steve Silvia and Alan Lintala took photographs. Dr. Frank Schwartz graciously loaned us radiographs of his deformed specimens. Ms. Susan Clements-Proulx and Mrs. Marge Kenyon typed the manuscript.

#### LITERATURE CITED

- APPLEGATE, S. P. 1967. A survey of shark hard parts. In *Sharks, Skates and Rays*, P. W. Gilbert, R. F. Mathewson, and D. P. Rall (eds.). Johns Hopkins Press, Baltimore, Maryland, pp. 37-67.
- BIGELOW, H. B., AND W. C. SCHROEDER. 1948. *Sharks. In Fishes of the Western North Atlantic, Part One*. H. B. Bigelow, W. C. Schroeder, and I. P. Farfante (eds.). Mem. Sears Found. Mar. Res. No. 1, pp. 1-576.
- CLARK, E. 1964. Spinal deformity noted in a bull shark. *Underwater Nat.* 2: 25-28.
- DAWSON, C. E. 1964. A bibliography of anomalies of fishes. *Gulf Res. Rep.* 1: 308-399.
- . 1966. A bibliography of anomalies of fishes. Supplement 1. *Gulf Res. Rep.* 2: 169-176.
- . 1971. A bibliography of anomalies of fishes. Supplement 2. *Gulf Res. Rep.* 3: 215-239.
- . 1976. A bibliography of anomalies of fishes. Supplement 3. *Gulf Res. Rep.* 5: 35-41.
- HOENIG, J. M. 1979. The Vertebral Centra of Sharks and Their Use in Age Determination. M.S. Thesis. University of Rhode Island, Kingston, Rhode Island, 144 pp.
- LAWLER, E. F., JR. 1976. The Biology of the Sandbar Shark, *Carcharhinus plumbeus* (Nardo, 1827) in the Lower Chesapeake Bay and Adjacent Waters. M.S. Thesis. College of William and Mary, Williamsburg, Virginia, 49 pp.
- NEEDHAM, T., AND R. WOOTTEN. 1978. The parasitology of teleosts. In *Fish Pathology*, R. J. Roberts (ed.). Bailliere Tindall, London, England, pp. 144-182.
- RIDEWOOD, W. B. 1921. On the calcification of the vertebral centra in sharks and rays. *Philos. Trans. R. Soc. B* 210: 311-407.
- RONSIVALLI, L. J. 1978. Sharks and their utilization. *Mar. Fish. Rev.* 40: 1-14.
- SADOWSKY, V. 1971. Notes on the bull shark *Carcharhinus leucas* in the lagoon region of Cananea, Brazil. *Bol. Inst. Oceanogr.* 20: 71-78.
- SCHWARTZ, F. J. 1973. Spinal and cranial deformities in the elasmobranchs *Carcharhinus leucas*, *Squalus acanthias*, and *Carcharhinus milberti*. *J. Elisha Mitchell Sci. Soc.* 89: 74-77.
- SPRINGER, S. 1960. Natural history of the sandbar shark, *Eulamia milberti*. U.S. Fish. Wildl. Serv. Fish. Bull. 61: 1-38.
- STEVENS, J. D. 1975. Vertebral rings as a means of age determination in the blue shark (*Prionace glauca* L.). *J. Mar. Biol. Assoc. U.K.* 55: 657-665.